



# Resident Review

Cutting Edge Orthopaedic Information Enhancing Resident Education

## From the Editor

Kristan A. Pierz, MD



Kristan A. Pierz, MD

Winter is finally winding down and spring is just around the corner. With the change of season, it's time for new growth and fresh new ideas. Here at the Pediatric Orthopaedic Society of North America (POSNA), we realize that education and training are constantly changing. Published twice each year, Resident Review strives

to keep residents and fellows informed of such changes within the field pediatric orthopaedics. In this issue, Dr. Robert Carrigan's interview with POSNA's past president Dr. John (Jack) Flynn, and Dr. Pooya Hosseinzadeh's interview with Drs. Ernest Sink, Young Jo Kim, and Mininder Kocher highlight the trend for sub-specialization that is occurring in fellowship training. Pediatric orthopaedics still appeals to many because of the variety of conditions that one encounters, yet others are equally excited about focusing their efforts to become experts in specialty areas. If cutting edge technology excites you, you will find Dr. Kevin Neal's interview with Dr. Randal Betz particularly interesting. In this article, Dr. Betz describes novel vertebral body tethering surgery – a technique that is currently only being done in a limited number of centers but sparking interest all over.

Although advances in technology can be exciting, keeping up with all of the changes can be overwhelming. Fortunately, we are lucky to have Dr. Orrin Franko's Technology Corner to help us make sense of all of the latest gadgets and apps. Dr. Franko's semi-annual column offers practical information to tech users of all levels. This edition of Resident Review also offers a new column called Top Picks. In this column, the contributors have selected articles from the past year that they found particularly interesting. Whether it's for the quality

*continued on page 7*

## Technology Corner: Taking Your Smartphone to the Next Level

By Orrin Franko, MD

As residents, the habits we develop in training will continue throughout our career – and this applies to our personal life as much as it applies to our professional endeavors. Considering the time commitment required of our roles as residents and attending surgeons, a small investment in time-efficient habits can yield significant returns. Enter the smartphone. Most residents are comfortable using their device for basic tasks, such as email, calendar, and quick-reference orthopaedic knowledge on-the-go. But, have you thought about stepping it up a level and using your devices for full desktop file access, slide presentations, scanning documents, optical character recognition, and more? Read on to learn how recent apps can simplify your life and enhance your work flow.



Orrin Franko, MD

Most residents utilize the basic iPhone email and calendar apps on a daily basis without considering their limitations and inefficiencies. However, for less than \$10, there are superior apps that can enhance your efficiency and organization. Two of the popular calendar apps are Fantastical 2 and Calendars 5. I use Fantastical 2 and love its natural language input when creating events. For example, utilizing the voice dictation tool I can speak into my phone "I am on call from 5pm to 6am at County Hospital every Tuesday until March 1st" and the app will automatically understand and create the events in one step. The app also has a far-superior user-interface compared to the default iOS calendar, and easily integrates with your entire existing calendar accounts without any additional setup. I consider an enhanced calendar a "must have" for anyone, and Fantastical 2 is a great choice. Similarly, there exist a number of enhanced email apps, such as CloudMagic, Mailbox, Gmail, and many others. Most offer various features for

*continued on page 7*

## Five Questions about Subspecialty Training

By Robert B. Carrigan, MD

In recent years, there has been increasing interest among pediatric orthopaedic fellowship applicants to pursue subspecialty training. Many applicants consider secondary fellowships in a variety of disciplines to further their surgical training. I had the opportunity to interview former POSNA President John (Jack) M. Flynn, MD about this topic.

*Q: In your 18 years as an educator, of both residents and fellows, has the interest in pediatric orthopaedic fellows pursuing secondary fellowships in subspecialties increased?*

**A:** Without a doubt, the interest in subspecialty training and subspecialty practice has increased dramatically since I entered the field of pediatric orthopaedics in the mid-90s. 20 years ago, we knew of only one true pediatric sports medicine surgeon (Lyle Micheli in Boston). There were several experts in pediatric hand, pediatric hip and pediatric spine, but the vast majority also practiced general pediatric orthopedic surgery and took general pediatric orthopedic surgery call for their institution.

As the musculoskeletal care of children and adolescents rapidly migrated out of the community and into children's hospitals, the orthopaedic surgeons at children's hospitals have developed subspecialty expertise in order to build their practice and differentiate themselves from their partners. This has had a very positive effect in the growth of subspecialty knowledge and certain surgical skills, but a detrimental effect on the unity among pediatric orthopaedic surgeons in practice, and the ability to create meaningful CME that is of interest to all pediatric orthopaedic surgeons.

*Q: What secondary fellowships are being pursued most often?*

**A:** Recently, Glotzbecker et al\* completed a study of recent pediatric orthopaedic fellows. As part of the survey, they reported that 30% of pediatric orthopaedic fellows were pursuing a second fellowship, and the most common choice was spine, sports or hand.

*Q: Do you think the growing interest in pediatric subspecialty training stems from a growing demand from the public for super-subspecialists or limitations in fellowship training as a result of duty hour restrictions?*



*John (Jack) M. Flynn, MD*

**A:** Neither. I've discussed second fellowships with many residents, fellow applicants and young pediatric orthopaedists in practice. While some of the interest in the second fellowships results from a true passion for a particular area of pediatric orthopaedics (e.g. neuromuscular, hip, sports), in most cases the second fellowship is done to position the fellow as an expert in a subspecialty so that they will be an attractive hire. So, in a way, it comes down to geography. If the budding pediatric orthopaedist aspires to practice in an area dominated by a small group of general pediatric orthopaedists (common in less populous regions), a second fellowship is probably not necessary. However, if the young pediatric orthopaedists are interested in practicing at one of the very large pediatric orthopaedic centers, he or she will almost surely need subspecialty expertise to be of maximum value to the group and to best develop a robust practice in the future.

Duty hour restrictions have impacted other fellowships, but not really pediatric orthopaedics. Because duty hour restrictions have compromised overall surgical caseloads in many residency programs, self-aware graduates will pursue fellowships in adult reconstruction or adult sports medicine in order to be as well-trained for general orthopaedics as PGY5s used to be before the duty hour restrictions began. We don't see this in pediatric orthopaedics, because it does not really prepare the fellow for general orthopaedic practice in the community.

*continued on page 13*

## Emerging Technology: An Interview with Randal Betz, MD on the Vertebral Body Tethering Procedure

Pooya Hosseinzadeh, MD

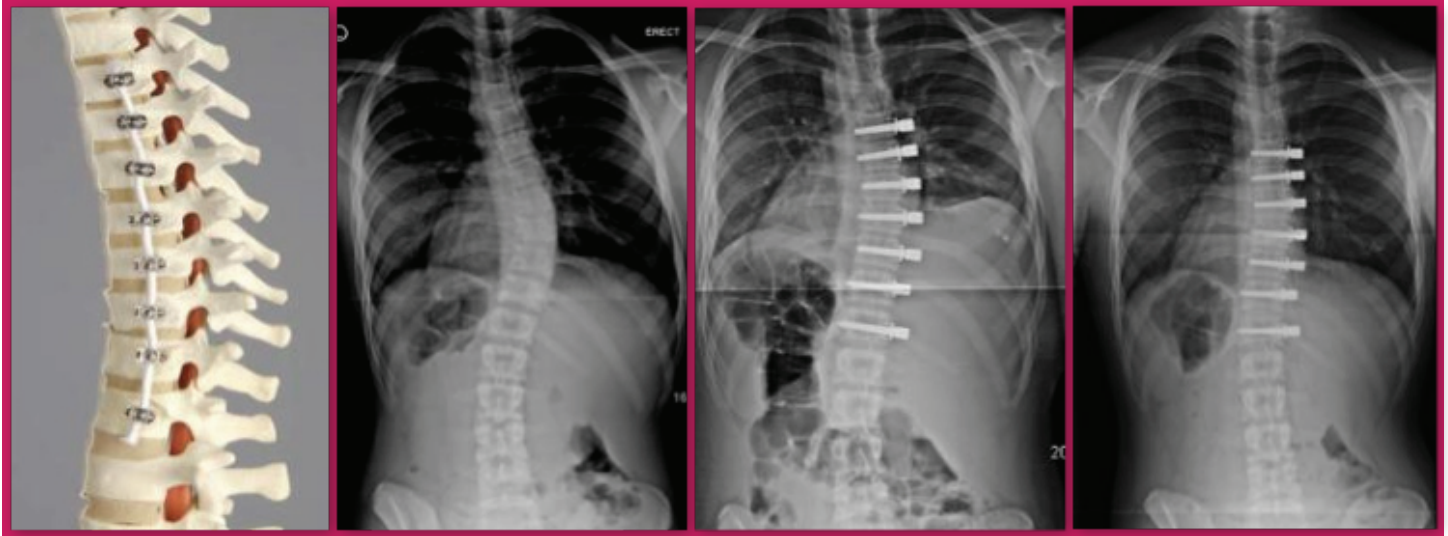


Figure 1: a) sagittal view of a spine model with intact pedicle screws and PET tether. b) 14yo girl with 38° thoracic scoliosis. c) 1st post-op X-Ray with residual curve 25° d) 2 years post-op with residual curve of 6°.

For decades, our traditional methods to treat idiopathic scoliosis have included only observation, bracing, or spinal fusion. More recently, another option, growth modulation, has gained popularity and interest.

The use of growth modulation for limb deformities is not new. Techniques for physal arrest date back at least 80 years and have evolved into the more common plate and screw techniques popular today. More recently, growth modulation techniques have been applied to the spine as well, creating a new category of scoliosis treatment. Efforts to modify spine growth include growing rod techniques, vertebral body stapling and, more recently, vertebral body tethering. The indications and results for vertebral body stapling have been published previously (Ref. 1-3). Vertebral body tethering, the newest technique, will be discussed here.

**Vertebral Body Tethering** is a technique in which pedicle screws are placed into the anterior vertebral bodies (usually thoroscopically) and are attached to a flexible, polyethylene-terephthalate (PET) cable on the convexity of the curve. The cable is tightened, providing some immediate improvement in the curvature. The cable tethers the convexity and allows the concavity to continue growing, further decreasing the size of the curve over time (Figures 1a-d).

In general, the procedure is most likely to benefit patients whose skeletal immaturity and curve size suggest that

they will progress beyond the traditional threshold for posterior spinal fusion despite bracing.

Dr. Randal Betz, formerly of Shriners Hospitals for Children-Philadelphia, and now with the Institute for Spine & Scoliosis in Lawrenceville, New Jersey, was one of the first surgeons to employ the vertebral body tethering technique for his patients with spine deformity.

*I recently spoke with Dr. Betz about his experience:*

**Q:** *Dr. Betz, how did you first get interested in vertebral body tethering?*

**A:** I was seeing a lot of patients who were struggling with brace wear, so I was searching for other alternatives for nine or ten year olds who were looking at wearing a brace for four or five years. I became interested in vertebral body stapling around 2001. After I started doing this procedure, I learned that the staples worked well for thoracic curves under 35°. However, they were not powerful enough to control curves over 35°, so I began looking for another option. I thought the Zimmer Dynesys system, which had FDA approval for low back surgery, would be a perfect device for tethering. In 2011, I talked to Dr. John Braun in Vermont, and he had just started doing the same exact thing. So, we started doing them at Shriners Hospital-Philadelphia in February, 2011.

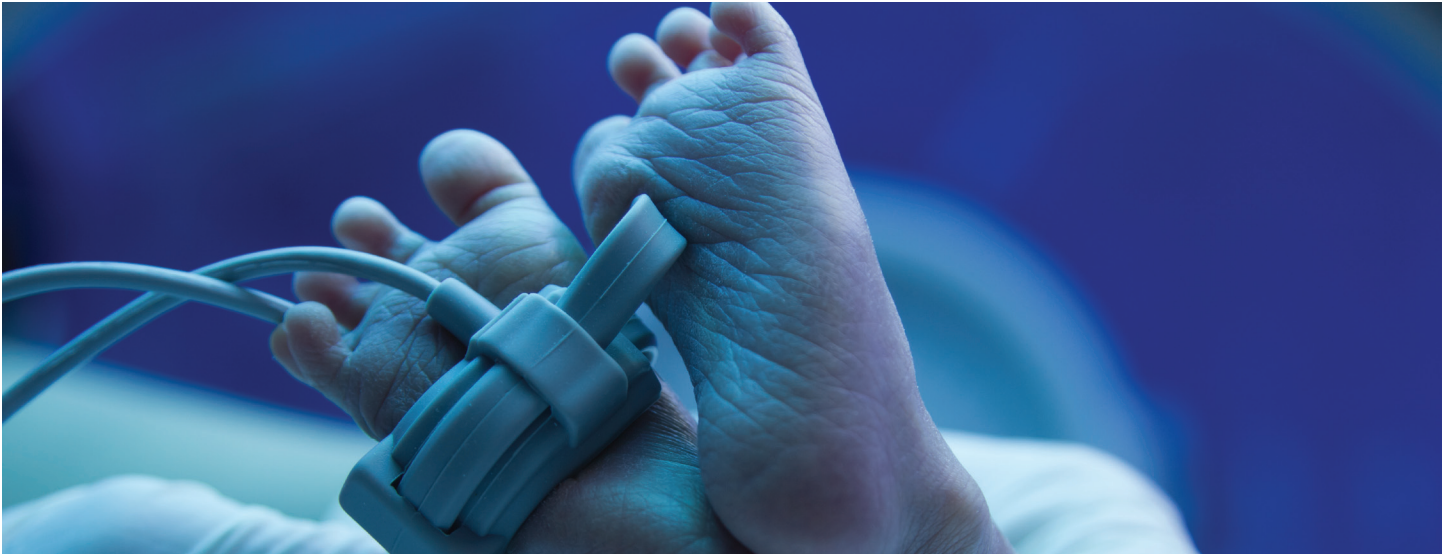*continued on page 14*



---

## Subspecialty Training in Pediatric Orthopaedics

By Pooya Hosseinzadeh, MD



Recently there has been an increase in the number of pediatric orthopaedic surgeons subspecializing in different areas of pediatric orthopaedics. Raw data from the POSNA Practice Management Committee has shown that close to 30% of recent graduates from pediatric orthopaedic fellowship programs decide to do a second fellowship which could potentially dramatically change the way pediatric orthopaedics is practiced in the United States. We have interviewed three pediatric orthopaedic surgeons who have established subspecialty practices to seek their opinion in this recent trend.

### Interview with Ernest L. Sink, MD, Pediatric and adolescent hip specialist, Hospital for Special Surgery

*Q: What are your thoughts about the recent trend toward subspecialization in pediatric orthopaedics? Do you support that trend?*

**A:** I do support the trend. Many of the procedures that pediatric orthopaedists are performing are increasing in complexity and risk. ***Specialization will increase volume and surgeon proficiency/safety for these procedures.*** The majority of pediatric orthopaedic procedures do not require subspecialization. I believe it is beneficial for procedures such as VCR in the spine, Modified Dunn for SCFE, skeletally immature ACL, or revision clubfoot. For these procedures, volume and systems that go with subspecialization are better for patient care. Education and research also benefit from subspecialization.

*Q: What made you decide to subspecialize in an area of pediatric orthopaedics?*

**A:** It was a natural decision to continue to learn about the hip, for which I found I had the most interest. I had great mentors (Dr. Robert Eilert, Dr. Mark Erickson, and Dr. Dennis Wenger) who directed me toward subspecialization because they were able to help me identify and support my interest. I was fortunate to spend time with Dr. Millis and Professor Ganz who became mentors and role models. ***I had a true interest and enjoyment in the patients, pathology, and surgery of the hip, thus I followed my innate passion.***

*Q: What do you see as the cause of the recent trend toward subspecialization in pediatric orthopaedics?*

**A:** I think it is a combination of surgeons finding enjoyment in specific pathologies and surgeries, mentorship, and development of complex procedures that require volume. At each academic center a specific surgeon(s) will develop their niche and increase their knowledge, research, and education regarding their subspecialization.

*Q: What percentage of your current practice is dedicated to general pediatric orthopaedics?*

**A:** 15-20 percent.

*Q: Do you have any comments that you would like to add?*

**A:** ***I believe that subspecialization is not necessary to have a successful and enjoyable pediatric orthopaedic practice.*** The type and location of the practice are factors that play a role in subspecialization.

---

**Interview with Young Jo Kim, MD, Pediatric and adolescent hip specialist, Boston Children’s Hospital**

*Q: What are your thoughts about the recent trend toward subspecialization in pediatric orthopaedics? Do you support that trend?*

**A:** *I think the trend toward specialization is natural as the treatment becomes more complex and technically demanding.* I think in the future we will have specialization for certain regions, such as hip, that span from children to young adults. We will also have specialization in disease conditions such as neuromuscular disease where a more holistic approach is necessary.

*Q: What made you decide to subspecialize in an area of pediatric orthopaedics?*

**A:** I did it mostly because I enjoyed understanding disease processes and I very much enjoyed the people in pediatric orthopaedics. When I decided to go into pediatrics, it was definitely not a popular thing to do. Many of my co-residents questioned my choice. However, ultimately you have to do what you enjoy and it seemed to have worked out for me.

*Q: What do you see as the cause of the recent trend toward subspecialization in pediatric orthopaedics?*

**A:** I think the technical demands are higher, especially in spine and hip. *Also, I think there is a trend toward expanding pediatric orthopaedics into the adolescent and young adult age range; hence, you need to be familiar with the modern adult techniques.*

*Q: What percentage of your current practice is dedicated to general pediatric orthopaedics?*

**A:** I still do quite a bit of trauma and some lower extremity deformity work. I would say about 30-40% of my volume is considered general pediatric orthopaedics.

**Interview with Mininder Kocher, MD, Pediatric sports medicine specialist, Boston Children’s Hospital**

*Q: What are your thoughts about the recent trend toward subspecialization in pediatric orthopaedics? Do you support that trend?*

**A:** When I trained in the 90s, it was unusual to have a

subspecialty practice in pediatric orthopaedics. *It is one of the great aspects of pediatric orthopaedics that you have the option of doing general pediatric orthopaedics versus subspecializing in one area.* I think I support the trend because it gives more options to people interested in pediatric orthopaedics.

*Q: What made you decide to subspecialize in an area of pediatric orthopaedics?*

**A:** I had difficulty choosing between sports medicine and pediatrics fellowships during residency. Rotation at Boston Children’s Hospital made me like pediatrics but I also enjoyed arthroscopic procedures. After finishing my pediatric orthopaedic fellowship, my mentors encouraged me to train in sports medicine and start a pediatric sports medicine practice at Boston Children’s Hospital.

*Q: What do you see as the cause of the recent trend toward subspecialization in pediatric orthopaedics?*

**A:** I think we see that because people started doing two fellowships and this created a path for people with different interests. People have different orientations, some enjoy doing a variety of procedures and will get bored doing only a limited number of procedures. On the other hand, some people prefer to dig deep in one area and develop a subspecialty practice.

*Q: What percentage of your current practice is dedicated to general pediatric orthopaedics?*

**A:** The first five years of my practice was mostly general pediatric orthopaedics but now the majority of my practice is limited to pediatric sports medicine. I perform close to 650 surgeries a year. I see and treat some general pediatric orthopaedic pathologies in my sports practice (varus/valgus deformities). I also take call and perform emergent pediatric orthopaedic procedures.

*Q: Do you have any comments that you would like to add?*

**A:** This trend is good for pediatric orthopaedics since it gives interested people more options to choose from. *I also treat college athletes and my partners with subspecialty practice in adolescent hip also treat young adults. This shows an expansion of what traditionally was considered as pediatric orthopaedics.* ■

---

***“... It is one of the great aspects of pediatric orthopaedics that you have the option of doing general pediatric orthopaedics versus subspecializing in one area...”***

---

## Top Picks

With so many articles in so many journals, it's hard to keep up on all of the latest research in orthopaedics. We often find ourselves reading only certain journals or articles specifically for a purpose such as preparing for a case, conference, or journal club. Every now and then, however, we come across an article that catches our interest or stimulates curiosity. We surveyed the members of POSNA's Resident Review Committee and asked them what articles they would recommend to residents and fellows for reading. Here are a few they came up with:

- 1. Best Practices in Intraoperative Neuromonitoring in Spine Deformity Surgery: Development of an Intraoperative Checklist to Optimize Response**  
*Vitale, Michael G. et al.*  
*Spine Deformity*, Volume 2, Issue 5, 333 – 339
- 2. Relationship of Calcaneal and Iliac Apophyseal Ossification to Peak Height Velocity Timing in Children**  
*Allen D. Nicholson, BS; Raymond W. Liu, MD; James O. Sanders, MD; Daniel R. Cooperman, MD*  
*J Bone Joint Surg Am*, 2015 Jan 21; 97 (2): 147 -154.  
<http://dx.doi.org/10.2106/JBJS.N.00671>
- 3. A Critical Appraisal of the First-year Experience of 5 Pediatric Orthopaedic Surgeons**  
*Nicholas D. Fletcher, MD, Annalise N. Larson, MD, Michael P. Glotzbecker, MD, Benjamin J. Shore, MD, MPH, FRCSC, and Christopher R. Hydorn, MD*  
*J Pediatr Orthop*. 2014 Sep;34(6):655-9.
- 4. Surgical Site Infections After Posterior Spinal Fusion for Neuromuscular Scoliosis: A Thirty-Year Experience at a Single Institution**  
*Brandon A. Ramo, MD; David W. Roberts, MD; Dominick Tuason, MD; Anna McClung, RN, BSN; Lauren E. Paraison, BA; Harold G. Moore IV; Daniel J. Sucato, MD*  
*J Bone Joint Surg Am*, 2014 Dec 17;96(24):2038-2048.  
<http://dx.doi.org/10.2106/JBJS.N.00277>
- 5. Local Administration of Bone Morphogenetic Protein-2 and Bisphosphonate During Non-Weight-Bearing Treatment of Ischemic Osteonecrosis of the Femoral Head: An Experimental Investigation in Immature Pigs**  
*Harry K.W. Kim, MD, MS; Olumide Aruwajoye, MS; Justin Du; Nobuhiro Kamiya, MD, PhD*  
*J Bone Joint Surg Am*, 2014 Sep 17;96(18):1515-1524.  
<http://dx.doi.org/10.2106/JBJS.M.01361>
- 6. Glucocorticoid Treatment for the Prevention of Scoliosis in Children with Duchenne Muscular Dystrophy: Long-Term Follow-up**  
*David E. Lebel, MD, PhD; John A. Corston; Laura C. McAdam, MD, FRCPC; W. Douglas Biggar, MD, FRCPC; Benjamin A. Alman, MD, FRCSC*  
*J Bone Joint Surg Am*, 2013 Jun 19; 95 (12): 1057 -1061.  
<http://dx.doi.org/10.2106/JBJS.L.01577>



of the research, the novelty of the topic, or the unique perspective on an idea, we hope that you will enjoy these articles as much as we did. Maybe you'll be inspired to get involved in a research project of your own.

Finally, no issue of Resident Review would be complete without some questions to help you test your knowledge and practice your test-taking skills. Whether you are

studying for your in-training exam, the boards, or the maintenance of certification (MOC), it's always a good idea to do practice questions. Quiz yourself and your colleagues. We hope you have some fun learning and that you find the questions both interesting and challenging. If you have any comments or suggestions, please feel free to contact me at [kpierz@connecticutchildrens.org](mailto:kpierz@connecticutchildrens.org). ■

---

*Technology Corner: POSNA Educational Resources Review (from page 1)*

organizing, prioritizing, and sifting through emails and tasks. Interested readers should consider trying out a few (many are free).

If your primary computer was dropped into the ocean at this instant, how much critical data would you lose forever? If you answered anything but "none," you should seriously consider an automated cloud back-up solution. There exist a plethora of services that, once installed on your desktop or laptop computer, ensure every file you permit is automatically backed up in the cloud. I use SugarSync, and other popular services include iDrive, Carbonite, etc. Each product varies with regard to cost, storage space, and minor features, but all offer the same basic functionality of full-system backup with the ability to access files remotely and from mobile devices. I have found SugarSync most useful for accessing important documents when I am away from my computer, collaborating on research documents with colleagues (without having to email different version back and forth), and sharing photos with family and friends.

As a resident, I like to "travel light" and prefer not to carry a laptop around the hospital. However, laptops are often necessary for making PowerPoint slides and plugging into a projector... or are they? Recently, Microsoft has released iPad version of PowerPoint, Excel, and Word. While the free version limits your ability to save and edit files, I use PowerPoint to give presentations directly from my phone with the help of a VGA or HDMI dongle (sold separately). The phone is used as a slide controller for advancing slides, and includes a digital "laser pointer" feature that is sure to impress your audience. Give it a try the next



time you have to give a presentation. Taking photos with your phone is routine, but what about using those photos to scan documents or convert typed words into digital text? Recent advances in mobile cameras and optical character recognition make all of this possible for free. Apps such as DocScan and CamScanner can easily convert documents into high-quality PDF and JPG files, convert words into

digital text that can be pasted into emails or documents, and even allow you to fax those documents directly from your phone! One of my favorite features of these apps is the ability to integrate with other cloud services. For example, CamScanner can be set to automatically upload every scanned document into a pre-designated folder on DropBox, for example, which in turn can automatically download the file to your computer in one step. These features allow residents and surgeons to create a high-efficiency work flow for cataloguing expense receipts or archiving clinical patient images.

I hope you will find some of these suggestions useful. If you have other "tips and tricks" to share about increasing your smartphone efficiency in the hospital, please email them to: [orrrin@toporthoapps.com](mailto:orrrin@toporthoapps.com). ■

---

## Practice Questions:

No edition of Resident Review would be complete without a questions and answers section. Rather than focus on a single topic, the authors have written questions that cover a variety of basic science, physical exam, and practical issues. Enjoy the challenge!

### Question 1

---

A seven year old male presents three years after type III supracondylar fracture which underwent closed reduction and percutaneous pinning. His parents note a “deformity” of his arm, and are concerned with long term consequences. On exam his distal motor and sensory exam are intact; his elbow has full flexion and extension, supination and pronation. In extension, he demonstrates a radial prominence of the distal humerus and a varus angulation at the level of the elbow of approximately 15 degrees, versus neutral alignment in extension on the opposite side. This deformity is most likely secondary to:

- A) Overgrowth of the radial callous of the distal humerus fracture
- B) Differential growth following the fracture at the level of the elbow
- C) Malunion of the fracture at the time of treatment
- D) Infection at the level of the distal humerus

*Preferred answer: C*

**Discussion:** Residual cubitus varus following surgical treatment of a distal humerus supracondylar fracture is most often the result of malalignment at the time of reduction and pinning. Assymetry of healing or growth is uncommon in this setting.

#### References:

1. *J Pediatr Orthop.* 1982;2(5):539-46. Cubitus varus deformity following supracondylar fractures of the humerus in children. Labelle H, Bunnell WP, Duhaime M, Poitras B.

### Question 2

---

A ten week old infant boy presents with his head tilted over his left shoulder that has been present since birth and plagiocephaly. Physical exam reveals a non-painful fullness in the left neck area. The child is otherwise happy and moves his arms and legs symmetrically. Initial treatment recommendations should include:

- A) Brain and spine MRI
- B) Bilateral hip ultrasound
- C) Flexion and extension cervical spine films
- D) A cervicothoracic orthosis
- E) Bipolar sternocleidomastoid release

*Preferred answer: B*

**Discussion:** The child likely has congenital muscular torticollis. The non-painful fullness, often described as an olive, likely represents swelling of the body of the SCM muscle and as the child ages often is replaced by a tight fibrotic band. The treatment of congenital torticollis involves a stretching program, which resolves the problem in approximately 90% of patients. The clinical presentation is often sufficient to make the diagnosis, with more extensive workup being reserved for atypical presentations or patients refractory to stretching. Simple AP and lateral C-spine radiographs can be considered to screen for congenital vertebral abnormalities, but these can be difficult to obtain and interpret in infants this young. Ultrasound can also be helpful in assessing and following the SCM muscle fibrosis. Surgical treatment should be reserved for refractory cases in older children; Tachdjian’s Pediatric Orthopaedics recommends five years of age as the lower age limit for surgery. Congenital torticollis is associated with developmental dysplasia of the hip, 12% in a recent study, and at this age a bilateral hip ultrasound should be performed.

#### References:

1. Sankar WN, Weiss J, Skaggs DL. Orthopaedic conditions in the newborn. *J Am Acad Orthop Surg.* 2009 Feb; 17(2):112-22.
2. Tachdjian’s Pediatric Orthopaedics, 4th ed. Pg 216-221.
3. Joiner ER, Andras LM, Skaggs DL. Screening for hip dysplasia in congenital muscular torticollis: is physical exam enough? *J Child Orthop.* 2014 Mar; 8(2): 115-9.

### Question 3

---

Which reflex disappears first?

- A) Palmar grasp
- B) Stepping
- C) Plantar grasp
- D) Moro
- E) Tonic neck

*Preferred answer: B*

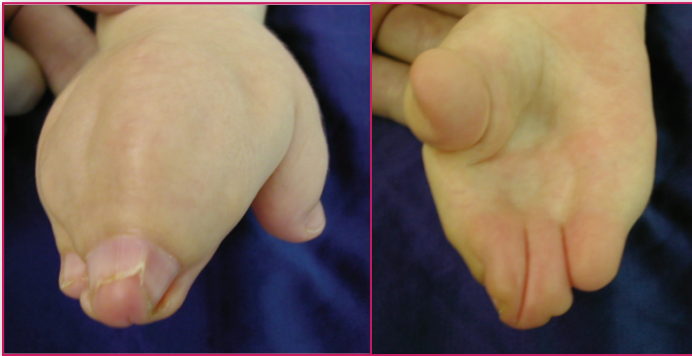

**Discussion:** When evaluating infants, it is important to know when primitive reflexes typically extinguish. The reflexes disappear in the following order: stepping at about six weeks, Moro at two-three months, tonic neck at about four months, palmar grasp at five-six months and plantar grasp at about one year.

#### Question 4

1. The patient pictured below has a defect in:

- A) Heparin sulfate metabolism
- B) Zone of polarizing activity (ZPA)
- C) Fibroblast growth factor receptors
- D) Synthesis of Sonic Hedgehog (Shh) Protein
- E) TBX-5 gene



*Preferred answer: C*

**Discussion:** This patient has Apert's syndrome (acrocephalosyndactyly), an autosomal dominant condition with a prevalence of 1:70,000. A defect in fibroblast growth factor (FGFR-2) has been implicated in this condition. Patients have characteristic hands and faces. Syndactyly of the hand ranging in severity, from simple to complex typically involves more than one digit and often the entire hand. Craniosynostosis are common as is mid-face hypoplasia. Defects in the zone of polarizing activity (ZPA) and Sonic Hedge Hog (Shh) protein express as patterning defects such as duplication and mirror hands. TBX-5 gene has been implicated in Holt-Oram syndrome, a combination of heart defects and simple syndactyly.

#### References:

1. Ibrahim OA, Chin ES, McCarthy JG, Mohammadi M. Understanding the molecular basis of Apert syndrome. *Plast Reconstr Surg* 2005;115:264-270.
2. Al-Qattan MM, Yang Y, Kozin SH. Embryology of the upper limb. *J Hand Surg Am.* 2009 Sep;34(7):1340-50.

#### Question 5

A positive Trendelenburg gait is seen when:

- A) The pelvis drops on the stance side when standing on one leg
- B) The pelvis drops on the contralateral stance side when standing on one leg
- C) The trunk lurches to the weakened side during gait
- D) The trunk lurches to the stronger side during gait
- E) The pelvis rises on the stance side when standing on one leg

*Preferred answer: C*

**Discussion:** In a Trendelenburg gait, the trunk lurches to the weakened side during gait. Weakness or pain may result in decreased firing of the abductor muscles. In order to keep the body from falling toward the unsupported side, the body weight is shifted over the weakened side. The trunk is a large mass that, when shifted, can balance the body weight over the weak side rather than rely on hip abductor contraction.

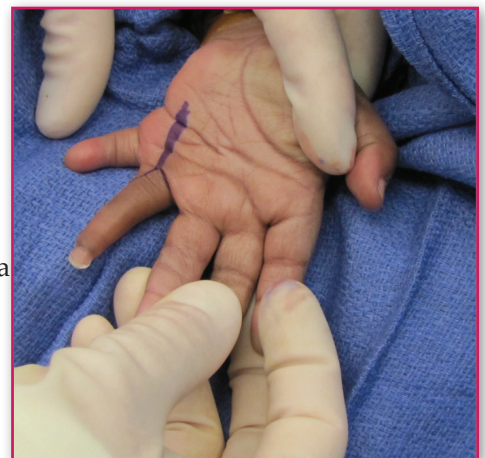#### Question 6

2. The patient pictured below has a defect in:

- A) Zone of polarizing activity
- B) Apical ectodermal ridge
- C) Wnt-7a/en-1 pathway
- D) TBX-5 gene
- E) Mucopolysaccharide processing

*Preferred answer: C*

**Discussion:** The patient has a defect in dorsal/ventral patterning (nail elements on the palmar aspect of the hand). The Wnt-7a pathway controls dorsal/ventral patterning. Wnt-7a is responsible for the development of dorsal elements such as the nail. An inhibitory protein en-1 is expressed in the volar aspect of the hand and blocks the development of dorsal structures volarly. Lack of expression of this inhibitory protein leads to development of dorsal structures volarly.



*continued on page 10*

## Practice Questions: (from page 9)

Defects in the zone of polarizing activity (ZPA) create radio/ulnar-patterning defects such as duplication. Defects in the apical ectodermal ridge (AER) are responsible for alterations in the longitudinal growth of the limb and are seen in cases of transverse deficiencies and cleft hand. Muccopolysaccharide processing defects are seen in mucopolysaccharidosis (MPS) a subset of lysosomal storage diseases, though these diseases affect the hands, volar nail elements are not observed.

### References:

1. Daluiski A, Yi SE, Lyons KM. The molecular control of upper extremity development: implications for congenital hand anomalies. *J Hand Surg* 2001;26A:8-22.
2. Al-Qattan MML, Yang Y, Kozin SH. Embryology of the upper limb. *J Hand Surg Am*. 2009 Sep;34(7):1340-50.

## Question 7

Which of the following about casting technique is true?

- A) Plaster casts can and should be applied in the same fashion as fiberglass casts
- B) Fiberglass casts should be applied in a stretch-relax technique
- C) When applying a spica cast for a femur fracture, a below knee cast should be applied first to produce distraction at the fracture
- D) There is no risk of compartment syndrome when treating a pediatric femur fracture in 90/90 (hip and knee at 90 degrees) spica cast

Preferred answer: B

**Discussion:** The principal pitfall of the use of fiberglass is clearly related to technique of application. In a prosthetic model of the lower extremity, skin surface pressure beneath a cast was measured by Davids et al. They recommend that fiberglass casts should not be applied in the same fashion as plaster casts. Fiberglass should be applied in a "stretch-relax technique." In this technique, the fiberglass is pulled away from the limb and then laid onto and around the limb. This technique significantly decreases the pressure under a cast.

Mubarak, et al. presented a series of nine patients treated for femur fractures with a 90/90 spica cast with a technique of an initial below knee cast to apply traction. These nine patients developed compartment syndromes, Volkmann contractures, and ankle skin necrosis. Based on this, the authors recommend a change of technique to 45 degree angle of hip and knee flexion and not utilize casts as a skin traction device.

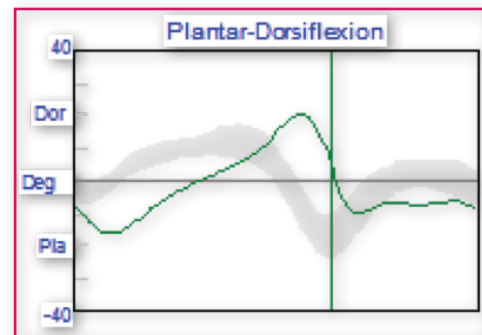
### References:

1. Davids, et al. Skin Surface Pressure Beneath an Above-the-knee Cast: Plaster Casts Compared with Fiberglass Casts. *JBJS* 1997; 79(4): 565-9.
2. Mubarak, et al. Volkmann Contracture and Compartment Syndromes after femur fractures in Children Treated with 90/90 spica casts. *JPO* 2006; 26 (5): 567-72.

## Question 8

Gait analysis of a patient with Charcot-Marie-Tooth disease demonstrating the following kinematic ankle plot likely has:

- A) Plantarflexor weakness
- B) Toe walking
- C) Crouch gait
- D) A&B
- E) A&C



Preferred answer: D

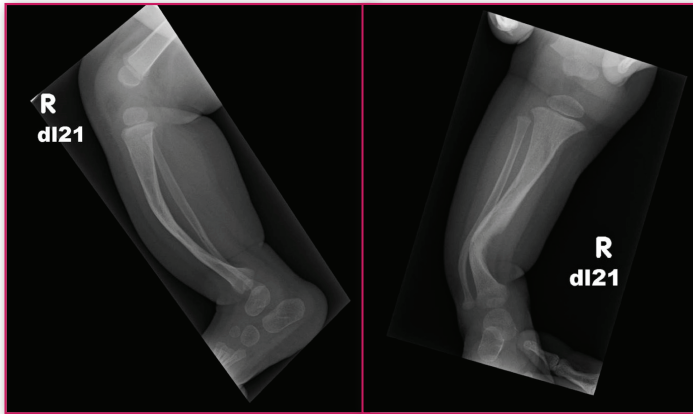
**Discussion:** The ankle kinematic plot demonstrates excessive plantarflexion in the first half of stance, which is consistent with toe walking. Patients with Charcot-Marie-Tooth (also known as hereditary sensory motor neuropathy) frequently develop cavus contractures with plantarflexed metatarsals. Due to plantarflexor weakness, there is a delay in peak dorsiflexion and delayed heel rise (push off) in terminal stance. The drop foot (equinus) in swing may be due to ankle dorsiflexor weakness or plantarflexor tightness. Crouch gait is characterized by excessive ankle dorsiflexion in stance combined with knee flexion and is often associated with cerebral palsy, especially in individuals with over-lengthened Achilles tendons.

### References:

1. Öunpuu S, Garibay E, Solomito M, Bell K, Pierz K, Thomson T, Acsadi G, DeLuca P. A comprehensive evaluation of the variation in ankle function during gait in children and youth with Charcot-Marie-Tooth disease. *Gait and Posture*, 2013, 38(213): 900-906.

### Question 9

A six month old female presents with a right lower leg deformity. Radiographs are below. What other clinical finding may be associated with the aforementioned abnormality?



- A) Multiple café au lait spots
- B) Absent lateral toes
- C) Congenital scoliosis
- D) Hitchhiker thumb
- E) Champagne glass pelvis

*Preferred answer: A*

**Discussion:** The radiographs show anterolateral bowing of the tibia, which has a high association with neurofibromatosis type 1. Approximately 55-75% of cases of anterolateral bowing and pseudarthrosis are associated with neurofibromatosis. Multiple café au lait spots are present in nearly all individuals with NF-1. While NF-1 is also highly associated with scoliosis and spinal deformity, it tends to be dysplastic or idiopathic in nature. Absent lateral rays as well as anterior or anteromedial bowing can be seen in fibular hemimelia and postaxial hypoplasia. Hitchhiker thumb in pediatric orthopaedics is a term that is associated with diastrophic dysplasia, caused by a short triangular 1st metacarpal that leads to radial subluxation of the metacarpal-phalangeal joint. Champagne glass pelvis describes the squared iliac wings and the wide pelvic inlet that is characteristic of achondroplasia.

#### References:

1. Vander Have KL, Hensinger RN, Caird M, Johnston C, Farley FA. Congenital Pseudarthrosis of the Tibia. *J Am Acad Orthop Surg.* 2008 Apr; 16(4): 228-36.
2. Feldman DS, Jordan C, Fonseca L. Orthopaedic Manifestations of Neurofibromatosis type 1. *J Am Acad Orthop Surg.* 2010 Jun; 18(6): 346-57.
3. Tachdjian's Pediatric Orthopaedics, 4th ed. Pg. 1721.

### Question 10

There are a number of ways to reduce complications related to cast placement and removal. All of the following are true with the exception of:

- A) A high cast index (i.e. 0.9) can help to prevent complications such as loss of reduction
- B) Running the cast saw with a vacuum can result in faster cooling of the saw
- C) Cast saw blade cooling in ambient air alone can take up to two minutes
- D) The use of isopropyl alcohol or water on gauze to cool the cast saw blade can decrease the cooling time

*Preferred answer: A*

**Discussion:** Chess, et al. clearly demonstrated that fractures with a high cast index have an increased risk of displacement. Ideal cast index is ~0.7 (sagittal to coronal ratio of the cast). A well molded cast with a cast index near 0.7 is more likely to maintain reduction.

Thermal injuries are a major risk with cast removal. It is estimated that injuries occur in 0.7% of cast removals. Puddy, et al. recently demonstrated that a saw blade can take up to two minutes to completely cool to a safe temperature in ambient air. The use of a cast saw with a vacuum can drastically decrease the cooling time (14 seconds). Additionally, cooling the blade with water or 70% isopropyl alcohol gauze can decrease cooling time to nearly five seconds.

#### References:

1. Chess, et al. Short arm plaster cast for distal pediatric forearm fractures. *JPO* 1994; 14:211-3.
2. Puddy, et al. Cast saw burns: evaluation of simple techniques for reducing the risk of thermal injury. *JPO* 2014; 34(8): e63-6

### Question 11

Which of the following describes the mechanism behind clinical manifestation of Multiple Hereditary Exostosis?

- A) Over activation of PTHrp
- B) Activating mutation of FGF R3
- C) Mutation in Cartilage Oligomeric Protein
- D) Mutations in type X collagen

*Preferred answer: A*

**Discussion:** Mutations in Exostosin 1 (EXT1) decrease the interaction between Ihh and the extracellular matrix, increasing the range of Ihh signaling within the growth plate and create an extended proliferative zone due to excessive activation of PTHrP. This mutation is responsible

*continued on page 12*



Practice Questions: (from page 11)

for the skeletal deformities seen in multiple hereditary exostoses.

**References:**

1. Hilton, M.J., et al., *EXT1 regulates chondrocyte proliferation and differentiation during endochondral bone development. Bone*, 2005. 36(3): p. 379-86.

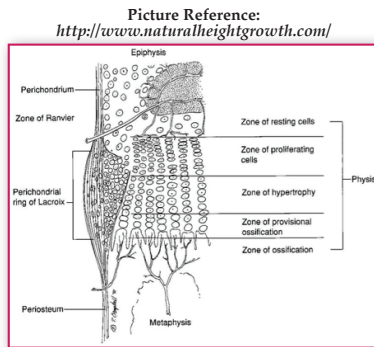
**Question 12**

In the hypertrophic zone of the physis, the:

- A) Cartilage cells are dividing rapidly.
- B) Chondrocytes begin to become organized into well-defined columns
- C) Collagen is primarily Type II
- D) Cells are most resistant to fracture
- E) Cartilage matrix begins to calcify

Preferred answer: C

**Discussion:** The hypertrophic zone is also called the maturation zone of the physis. There is no active cellular division in this layer. Rapid cell division occurs in the proliferative zone. In the hypertrophic zone, chondrocytes become enlarged and swollen, decreasing the ratio of the extracellular matrix to the volume of the cells. Though the chondrocytes remain in columns, column formation occurs in the proliferative zone. The collagen in the hypertrophic zone is primarily Type II, with a small amount of Type X as well. The hypertrophic zone is the most prone to physeal fracture. Calcification begins in the zone of provisional ossification.



**References:**

1. Iannotti JP. *Growth plate physiology and pathology. Orthop Clin North Am.* 1990 Jan;21(1):1-17.

**Question 12**

1) Which of the following mainly affects reserve zone of the growth plate?

- A) Leptin
- B) Thyroxin
- C) Ihh
- D) 24, 25 hydroxy vitamin D

Preferred answer: D

**Discussion:** Vitamin D has been shown to induce the proliferation and prevent the apoptosis of the chondrocytes in the reserve zone. This action is mainly done by the 24, 25 hydroxy vitamin D and not the 1, 25 hydroxy form.

Leptin and Thyroxin induce chondrocyte maturation and Ihh induces chondrocyte proliferation.

**References:**

1. Boyan, B.D., et al., *24R,25-dihydroxyvitamin D3 [24R,25(OH)2D3] controls growth plate development by inhibiting apoptosis in the reserve zone and stimulating response to 1alpha,25(OH)2D3 in hypertrophic cells. J Steroid Biochem Mol Biol*, 2010. 121(1-2): p. 212-6.

**Question 14**

1) The final ossification center to appear in the elbow of a growing child is the:

- A) Capitellum
- B) Radial head
- C) Medial epicondyle
- D) Olecranon
- E) Lateral epicondyle

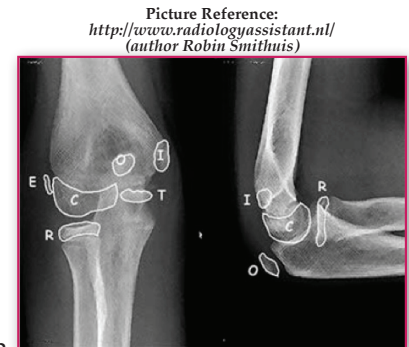
Preferred answer: D

**Discussion:**

The capitellar ossification center appears at about age five months in boys and four months in girls. The radial head ossification center appears at about age five years in boys and four years girls. The medial (internal) epicondylar center appears at about age seven years in boys and age five years in girls. The trochlear center appears at about age nine years in boys and age eight years in girls. The olecranon center appears at about age ten years in boys and eight years in girls. The lateral epicondylar center appears at about age 12 years in boys and 11 years in girls. Knowledge of the normal appearance of ossification centers is essential to interpret radiographs in the pediatric population. ■

**References:**

1. Herring, JA. *Chapter 1: Growth and Development. Pgs 3-22. In: Tachdjian's Pediatric Orthopaedics, 5th ed. Saunders. 2014.*



**Q:** What is POSNA doing to help guide residents and fellows seeking advice regarding secondary subspecialty training?

**A:** POSNA does not have a specific program, and that is appropriate. The advice comes primarily from mentors, who can be sought at the resident or fellow's program, or at the annual IPOS meeting. POSNA also just completed an extraordinary and comprehensive workforce assessment, led by Jeff Sawyer. Once this is published, current residents and fellows will have some outstanding current data available to make decisions.

**Q:** From a planning/manpower perspective, how does the growing number of subspecialty providers effect access to care for more generalized pediatric conditions?

**A:** We do not need to train pediatric orthopaedic surgeons to spend most of their week seeing non-operative conditions (in-toeing, etc.). It's not a good use of someone with six years of surgical training.

The best way to care for children and adolescents in the future is to take a group of pediatric orthopaedic surgeons and partner them with pediatric musculoskeletal primary care physicians. Surgeons

climb a learning curve toward competence and then need a critical mass of procedures to gain excellence as their careers progress. Simple procedures (tendon lengthening or elbow pinning) can be done by all pediatric orthopaedists, but complex spine deformity, PAOs, microvascular surgery, etc. should concentrate with those pediatric orthopaedists who have gained expertise through training and practice. We should work toward a strategy where highly skilled pediatric orthopaedic surgeons are busy in the operating room most of the week, see mostly pre-and postop surgical patients in the clinic, and serve in the trauma call rotation; most routine non-operative care is provided by primary care musculoskeletal physicians. We would be best served to move closer to the model of cardiothoracic surgeons and cardiologists. We will always have job security because no one will invent a pill or genetic treatment to prevent a child from jumping on a trampoline. ■

#### References:

1. Glotzbecker MP, S.B., Fletcher ND, Larson N, Hydorn CR, Sawyer JR, *What to Expect After Pediatric Orthopaedic Fellowship and Demand for their Services: A Survey of Fellowship Graduates (2012-13)*. Journal of Pediatric Orthopaedics, 2015. **Accepted for Publication.**

## 2015 Editorial Board

Robert B. Carrigan, MD  
Alice Chu, MD  
Steven L. Frick, MD  
John J. Grayhack, MD  
Christina K. Hardesty, MD  
Pooya Hosseinzadeh, MD  
Lori A. Karol, MD  
Kevin M. Neal, MD  
Jon Edward Oda, MD  
Kristan A. Pierz, MD - Editor  
Brian P. Scannell, MD  
James J. Tucci, MD



*Q: How many cases have you done?*

**A:** There is a collective experience of approximately 115 surgeries with Drs. Amer Samdani, Joshua Pahys, Patrick Cahill and myself at Shriners Hospital-Philadelphia, and with Dr. Darryl Antonacci in my current practice at The Institute for Spine & Scoliosis, in Lawrenceville, New Jersey.

*Q: How common is the vertebral body tethering surgery?*

**A:** Probably 20 surgeons have come and observed the procedure, and there may be eight who are currently doing at least one every quarter or so.

*Q: What are the indications for tethering?*

**A:** Our primary indication is a thoracic curve between 35° and 65° that bends below 30° on the bend film. Immaturity seems to be an important feature, because we're hypothesizing that if you tether the spine while the child is still growing, the vertebral bodies and the disk anatomy will become more normal. Also, if ten years down the line the tether breaks, it won't make much of a difference because the spinal anatomy has been relatively restored to normal.

*Q: Can the procedure be done in skeletally mature people?*

**A:** If you talk to orthodontists who are moving teeth, even in adults, they are seeing significant bone remodeling. It has encouraged us to consider that there may be some late remodeling opportunities, not just for growth modulation, but for bone remodeling. So even though in the past we were doing patients who were Risser 0, Sanders 4 or less, we now are considering patients who are a little bit older, Sanders 7 and up to Risser 4, because we just don't know how much remodeling there is in late adolescence.

*Q: Would you describe the procedure as a "fusionless cure" for scoliosis?*

**A:** I never use the word "cure." What I do tell patients is that it leaves them open to all options in the future. We haven't really had any failures yet, but should they arise, we have not "burned any bridges," and other treatments can still be considered. We tell patients that a spinal fusion is once and then hopefully done, but it's forever, and there may be issues with mobility down the road. At least with the tether, if something does start to fail, you can replace the tether and have not fused the spine.

*Q: In ten years, do you think this will be the standard treatment for idiopathic scoliosis patients with the curve size and maturity parameters you've described?*

**A:** I do, and I think the number of patients and indications will expand immensely. We've been doing primary lumbar and thoracolumbar curves. We've also been doing double-major curves, where we tether the thoracic curve on the right and the lumbar curve on the left. More recently, I've started doing what I call a "combo" for patients who have really stiff thoracic curves that are not amenable to the tether because they don't bend down below 30° and where they don't look like they're good candidates for selective fusion. (Remember that 42% of Lenke C curves that have had a selective thoracic fusion will decompensate the lumbar spine.) So the "combo" involves fusing the thoracic spine posteriorly and then tethering the lumbar spine. It's pretty new and pretty preliminary, but very exciting.

*Q: Are there any issues with the Zimmer Dynesys system being used in an off-label manner?*

**A:** The off-label status of Zimmer Dynesys shouldn't scare anyone away. The only thing the off-label designation does is prevent the company from formalizing the training. It requires that the surgeon take the initiative to attend a course and observe the procedure, and all of us doing it are very happy to take someone through the steps of learning how to do it appropriately. Of course, the insurance companies like to misuse the words "investigational" and "experimental." Peer to peer calls with the carrier MDs and quoting current published literature is the best route to counterbalance insurance denials.

*Q: What is the current status of development of an FDA-approved device for tethering?*

**A:** I am familiar with the regulatory efforts of DePuy Synthes Spine and Zimmer Spine. DePuy has started down the pathway to approval by doing the procedure on patients outside the US. I think they will eventually propose to the FDA a trial with fewer patients to prove efficacy, instead of a randomized controlled trial, which is cost-prohibitive. Zimmer Spine is preparing some protocols for studies to show safety and efficacy to submit to the FDA for a clearance pathway. I think it's still going to be at least two or three years before any vertebral body tethering system gets approved.

*Q: Is there anything else that you would like orthopaedic residents to know about spine tethering?*

**A:** This area of growth modulation is totally unexplored. We have absolutely no data on trying to use available markers to predict how much the spine is going to

---

*“...Hopefully, in ten years we'll have better tethers and technology that we can't even envision right now.”*

---



grow. For example, one significant problem is that sometimes we get overcorrection with tethering. We don't know exactly how much residual curve to leave in the OR. If you leave more than 30°, it may not end up being an outstanding result; it's probably not going to correct any further. However, if you make the spine too straight (for example, if you leave a ten year old with a 15° curve), it's probably going to overcorrect to beyond -10° and require lengthening. It would be nice to have some data on growth and would make for some excellent resident and fellow research projects. Especially with 3D X-rays, I think one could obtain really good data on growth.

*Q: What about the future improvements in tethering?*

*A: My vision is that in ten years we will have tethers that have more elasticity in them to accommodate different patients' bone growth and modulus of elasticity. Hopefully, in ten years we'll have better tethers and technology that we can't even envision right now. ■*

## Recommended Reading

1. *Betz RR, Kim J, D'Andrea LP, Mulcahey MJ, Balsara RK, Clements DH. An innovative technique of vertebral body stapling for the treatment of patients with adolescent idiopathic scoliosis: a feasibility, safety, and utility study. Spine (Phila Pa 1976) 28(20):S255-65, 2003.*
2. *Betz RR, Ranade A, Samdani AF, Chafetz R, D'Andrea LP, Gaughan JP, Asghar J, Grewal H, Mulcahey MJ. Vertebral body stapling: a fusionless treatment option for a growing child with moderate idiopathic scoliosis. Spine (Phila PA 1976) 35(2):169-76, 2010.*
3. *Theologis AA, Cahill P, Auriemma M, Betz R, Diab M. Vertebral body stapling in children with idiopathic scoliosis < 10 years of age with curve magnitude 30-39 degrees. Spine (Phila Pa 1976) 38(25):E1583-8, 2013.*
4. *Sanders JO, Khoury JG, Kishan S, Browne RH, Mooney JF 3rd, Arnold KD, McConnell SJ, Bauman JA, Finegold DN. Predicting scoliosis progression from skeletal maturity: a simplified classification during adolescence. J Bone Joint Surg Am. 90(3):540-53, 2008.*
5. *Samdani AF, Singla A, Ames R, Pahys JM, Betz RR. Early recognition of overcorrection after anterior vertebral body tethering. 48th annual Scoliosis Research Society meeting (case discussion), Lyon, France, September 18-21, 2013.*
6. *Samdani AF, Ames RJ, Kimball JS, Pahys JM, Grewal H, Pelletier GJ, Betz RR. Anterior vertebral body tethering for idiopathic scoliosis: two-year results. Spine (Phila Pa 1976) 39(20):1688-93, 2014.*
7. *Samdani AF, Ames RK, Kimball JS, Pahys JM, Grewal H, Pelletier GJ, Betz RR. Anterior vertebral body tethering for immature idiopathic scoliosis: one-year results on the first 32 patients. Eur Spine J 2014 Dec 16, Epub ahead of print.*